



# Severe Ebola virus disease with vascular leakage and multiorgan failure: treatment of a patient in intensive care

Timo Wolf, Gerrit Kann, Stephan Becker, Christoph Stephan, Hans-Reinhardt Brodt, Philipp de Leuw, Thomas Grünewald, Thomas Vogl, Volkhard A J Kempf, Oliver T Keppler, Kai Zacharowski

## Summary

**Background** In the current epidemic of Ebola virus disease in western Africa, many aid workers have become infected. Some of these aid workers have been transferred to specialised hospitals in Europe and the USA for intensified treatment, providing the potential for unique insight into the clinical course of Ebola virus disease under optimised supportive measures in isolation units.

**Methods** A 38-year-old male doctor who had contracted an Ebola virus infection in Sierra Leone was airlifted to University Hospital Frankfurt, Germany, on day 5 after disease onset. Within 72 h of admission to the hospital's high-level isolation unit, the patient developed signs of severe multiorgan failure, including lungs, kidneys, and gastrointestinal tract. In addition to clinical parameters, the diagnostic work-up included radiography, ultrasound, pulse contour cardiac output technology, and microbiological and clinical chemistry analyses. Respiratory failure with pulmonary oedema and biophysical evidence of vascular leak syndrome needed mechanical ventilation. The patient received a 3 day treatment course with FX06 (MChE-F4Pharma, Vienna, Austria), a fibrin-derived peptide under clinical development for vascular leak syndrome. After FX06 administration and concurrent detection of Ebola-virus-specific antibodies and a fall in viral load, vascular leak syndrome and respiratory parameters substantially improved. We gave broad-spectrum empiric antimicrobial therapy and the patient needed intermittent renal replacement therapy. The patient fully recovered.

**Findings** This case report shows the feasibility of delivery of successful intensive care therapy to patients with Ebola virus disease under biosafety level 4 conditions.

**Interpretation** The effective treatment of vascular leakage and multiorgan failure by combination of ventilatory support, antibiotic treatment, and renal replacement therapy can sustain a patient with severe Ebola virus disease until virological remission. FX06 could potentially be a valuable agent in contribution to supportive therapy.

**Funding** University Hospital of Frankfurt.

## Introduction

An epidemic caused by the Zaire strain of Ebola virus has struck three western African countries (Guinea, Sierra Leone, and Liberia) since December, 2013.<sup>1</sup> Several aid workers infected with Ebola virus were evacuated to specialised clinical units in Europe and the USA. Four case reports have documented the necessity for effective volume replacement in the treatment of Ebola virus disease.<sup>2-4</sup> The development of Gram-negative septicaemia and the need for non-invasive ventilation have also been reported.<sup>4</sup> In this report, we describe management of a very severe case of Ebola virus disease with the application of invasive ventilation, renal replacement therapy, and management of vascular leak syndrome.

## Patient history

The patient, a 38-year-old male doctor originally from Uganda, had worked in Lakka, Sierra Leone, for 3 years and was in charge of a treatment unit for Ebola virus disease. On Sept 28, 2014, he developed acute fever (38.1°C) and four episodes of diarrhoea. He tested positive for Ebola virus with RNA PCR on the same day (day 1 of disease onset). No particular exposure was

known and the source of infection remains unclear. The initial PCR result from serum was positive for Ebola virus with a cycle threshold value of 31.61. Malaria was excluded by antigen testing. Over the next 4 days, the patient developed nausea and vomiting and complained about increasing myalgia and malaise. On the basis of in-vitro data suggesting an antiviral effect of amiodarone,<sup>5</sup> the patient self-initiated treatment with 400 mg amiodarone orally followed roughly 6 h later by an intravenous bolus of 1200 mg and then a continuous infusion of 1200 mg over 24 h. In the Lakka treatment unit, he also received oral rehydration solution, 1 L of Ringer lactate substituted with 15 mmol potassium three times daily, and one dose of 2 g ceftriaxone daily from day 1 of the disease. Paracetamol 1 g and hyoscine bromide 20 mg intravenously were given as needed. The patient was airlifted to Frankfurt University Hospital for intensified treatment and arrived on day 6 after disease onset, having received fluids, metamizole (orally), and morphine (intravenously) during the flight. We recorded no important past medical history except for several episodes of malaria. The patient was not receiving any regular medication.

Published Online  
December 19, 2014  
[http://dx.doi.org/10.1016/S0140-6736\(14\)62384-9](http://dx.doi.org/10.1016/S0140-6736(14)62384-9)

See Online/Comment  
[http://dx.doi.org/10.1016/S0140-6736\(14\)62353-9](http://dx.doi.org/10.1016/S0140-6736(14)62353-9)

Department of Medicine, Infectious Diseases Unit (T Wolf MD, G Kann, C Stephan MD, H-R Brodt MD, P de Leuw MD), Department of Diagnostic and Interventional Radiology (T Vogl MD), Institute of Medical Microbiology and Infection Control (Prof V A J Kempf MD), Institute of Medical Virology (Prof O T Keppler MD), and Department of Anaesthesiology, Intensive Care Medicine and Pain Therapy (Prof K Zacharowski MD), University Hospital Frankfurt/Main, Germany; Institute of Virology and Germany Centre for Infection Research (DZIF), Partner Site Gießen-Marburg-Langen, Philipps University, Marburg, Germany (Prof S Becker MD); and Department of Infectious Diseases, Tropical Medicine and Nephrology, Hospital St Georg, Leipzig, Germany (T Grünewald MD)

Correspondence to:  
Prof Kai Zacharowski, Department of Anaesthesiology, Intensive Care Medicine and Pain Therapy, University Hospital Frankfurt, Theodor-Stern-Kai 7, 60590 Frankfurt am Main, Germany  
[kai.zacharowski@kgu.de](mailto:kai.zacharowski@kgu.de)

See Online for video

### Treatment setting

The patient was treated in a negative pressure room. Staff used positive pressure suits, boots, and a respirator hood as personal protective equipment whenever entering the isolation room. The respirator would only allow high-efficiency particulate absorption-filtered air into the hood and the suits. A triple layer of gloves including thick butyl nitrate gloves as the middle layer were applied. At least two members of staff were inside the isolation room permanently and did regular buddy checks of the personal protective equipment.

### Findings on admission

On admission, the patient was extremely weak but fully orientated. His body temperature was 39.0°C. He complained of severe myalgia and abdominal pain. His blood pressure was normal (132/92 mm Hg) with tachycardia of 120 beats per minute. An electrocardiogram showed a sinus rhythm without abnormalities and a QTc interval of 431 ms. He needed 3 L/min of oxygen during transportation. An initial blood test obtained during the administration of oxygen showed a PaO<sub>2</sub> of 10.75 kPa with a PCO<sub>2</sub> of 5.69 kPa; pH, base excess, bicarbonate, and lactate were within normal ranges. The oxygen was not switched off temporarily to obtain blood gases with room air because of the difficulties in obtaining an arterial blood sample while wearing a triple layer of gloves. There were small, left-sided pleural and pericardial effusions. The ejection fraction seemed to be decreased to roughly 50% in echocardiography.

Abdominal ultrasound showed fluid-filled intestines with extended walls of the small intestine (up to 8 mm), accompanied by increased mesenteric perfusion. Neither the small nor the large intestine showed any peristaltic loops and the intraluminal column of fluid was static. Intra-abdominal pressure was raised to 22 cm H<sub>2</sub>O. The abdomen was clinically very tender and serum amylase (175 U/L, reference range 14–97) was elevated; lipase could not be determined in the isolation setting.

The patient's mucous membranes were dry, without any signs of peripheral oedema. There were no signs of bleeding, pharyngitis, or skin rash. His urine output was 150 mL on initial bladder catheterisation, and no urinary output during the evacuation flight was reported.

The table shows the patient's baseline laboratory parameters. Initially, his leucocyte cell count was  $3.6 \times 10^9$  per L (reference 3.8–11.0), presenting 0.31% lymphocytes and 65% of neutrophils. Platelets were slightly low with  $104 \times 10^9$  per L (reference 163–337). The inflammatory parameters showed an increase in interleukin 6 (152 pg/mL) and a moderately elevated C-reactive protein (21 mg/L, reference <7). We noted mild hyponatraemia of 130 mmol/L (reference 135–145). Plasma creatinine was normal and albumin concentration was low at 27 g/L (reference 35–52 g/dL [2.7 g/dL, reference range 3.5–5.2 g/dL]). We noted a high concentration of protein and erythrocytes in the urine (dipstick analysis only).

	Values on admission	Reference range
<b>Full blood count</b>		
White blood count ( $\times 10^9$ /L)	3.6	3.8–11.0
Red blood count ( $\times 10^{12}$ /L)	4.20	4.8–5.9
Haemoglobin (g/L)	123	140–180
Hematocrit (fraction)	0.356	0.40–0.54
Mean cell volume (fL)	84.8	78–94
Platelet count ( $\times 10^9$ /L)	104	163–337
Lymphocytes ( $\times 10^9$ /L)	1.1	1.5–3.0
Neutrophils ( $\times 10^9$ /L)	2.3	3.0–5.8
Monocytes and other ( $\times 10^9$ /L)	0.2	..
<b>Number fraction</b>		
Lymphocytes	0.308	0.22–0.45
Neutrophils	0.646	0.54–0.62
Monocytes and other	0.046	..
<b>Electrolytes</b>		
Sodium (mmol/L)	130	135–145
Potassium (mmol/L)	4.8	3.6–5.1
Chloride (mmol/L)	99	96–110
Magnesium (mmol/L)	0.33	0.73–1.06
Calcium (mmol/L)	1.83	2.00–2.58
<b>Basic metabolics</b>		
Creatinine ( $\mu$ mol/L)	106	62–106
Blood urea nitrogen (mmol/L)	3	2–8 mmol/L
C-reactive protein (mg/L)	21	<7
Total protein (g/L)	58	61–81
Albumin (g/L)	27 (2.7 g/dL)	35–52 (3.5–5.2 g/dL)
Glucose (mmol/L)	5.9	4.1–6.6
<b>Liver panel</b>		
Alkaline phosphatase (U/L)	89	10–175
Alanine transaminase (U/L)	68	10–47
Amylase (U/L)	175	14–97
Aspartate transaminase (U/L)	338	11–38
Total bilirubin ( $\mu$ mol/L)	9 (0.5 mg/dL)	3–25 (0.2–1.6 mg/dL)
$\gamma$ -glutamyl transpeptidase (U/L)	107	6–28

Table: Baseline laboratory results

Liver enzymes were elevated (alanine transaminase 68 U/L, reference 10–47; aspartate transaminase 338 U/L, reference 11–38) with a normal bilirubin concentration (9  $\mu$ mol/L, reference 3–25 [0.5 mg/dL, reference 0.2–1.6]). The Ebola virus plasma viral load was  $1.84 \times 10^8$  RNA copies per mL. We determined virus load according to a standard curve established by the National EBOV Reference Laboratory at Marburg, Department of Virology.

After arrival in Frankfurt we discontinued amiodarone because of potential cardiac side-effects and unclear antiviral potency in vivo, in view of the relatively high in-vitro half maximal inhibitory concentration (IC<sub>50</sub>) value of 0.25  $\mu$ g/mL.<sup>5</sup>

### Pulmonary failure caused by vascular leakage

On admission (day 6), the patient needed 3 L/min oxygen via a face mask, resulting in an arterial PaO<sub>2</sub> of 10.75 kPa. On day 9, his respiratory condition deteriorated. Although we introduced non-invasive ventilation (positive end-expiratory pressure 10 mbar, change in assisted spontaneous breathing 1 mbar) and increased the amount of oxygen to 3.5 L/min, his PaO<sub>2</sub> decreased further to 8.53 kPa within several hours. Clinically, the patient had dyspnoea associated with orthopnoea and hyperventilation (>40 breaths per min). Auscultation was not possible in the personal protective equipment. The pleural effusions progressed bilaterally to 3 cm and 3.5 cm. There was no progress of the pericardial effusion and no further decrease of the ejection fraction. Chest radiographs on day 6 and day 8 showed increasing signs of a pulmonary oedema. Early in the morning of day 9, sufficient oxygen uptake was no longer possible, resulting in the need for oral intubation and mechanical ventilation. The first arterial blood gas on the ventilator with an FIO<sub>2</sub> of 50% showed a PaO<sub>2</sub> of 8.93 kPa and a normal PCO<sub>2</sub>.

### Procedures

#### Chest radiography

All chest radiographs were taken in the anterior–posterior plane and scored by consensus of two fully certified radiologists, using a scoring system modified from the Murray lung injury score and the Ware data<sup>6,7</sup> without knowledge of clinical data. Cassettes were encased and sealed in double plastic sheeting before being brought into the isolation unit. On the way out, cassettes were disinfected in a multistep procedure with a virucidal agent (Perform; Schuelke, Norderstedt, Germany), leaving the plastic sheeting inside the unit.

#### Intubation

Wearing a full protective suit with triple gloves and respirator hood makes oral intubation a very challenging task. In preparation, we put the patient in a sitting position on non-invasive ventilation with 100% oxygen. A suction unit was established and in reach. In a rapid manoeuvre, the patient received 0.2 µg fentanyl, 200 mg propofol, and 80 mg rocuronium. After 60 s, we brought the patient into a supine position and did a laryngoscopy. The oral cavity was very dry without mucositis and the glottis area was full of thick mucous fibres, which had to be removed to achieve good vision of the vocal cords. The 8.0 tube (Vygon; Aachen, Germany) could be placed in the trachea and the black marks on the tube encircled the vocal cords. Immediately, we established mechanical ventilation. During the whole procedure, peripheral oxygen saturation was above 90%. Using laryngoscopic guidance, we successfully placed a gastric feeding tube.

Validation of a correct tracheal intubation proved difficult under these conditions. Auscultation was not

possible, with peripheral oxygen saturation and ventilation synchronic movements of the thorax being the only indirect signs. Continuous measurement of end tidal CO<sub>2</sub> concentrations was therefore desirable, but was not available in our isolation unit.

#### Arteriovenous access

Because of the inability to feel any pulsation when wearing protective gloves, we used a sonography-assisted approach. Under strictly aseptic conditions, we placed an arterial line into the brachial artery for measurements with fibre optical thermodilution catheter technique (PiCCO). A similar approach was done for insertion of central lines and Shaldon catheters into the internal jugular veins, which were needed for intravenous drug administration and renal replacement therapy, respectively.

#### Measurement of vascular leakage

Usually, vascular leakage is accompanied by serious hypotension, commonly associated with the need of intravenous infusion and vasopressor therapy. In our case, the patient received norepinephrine 0.5 µg/kg per min to maintain blood pressure. An instant and objective bedside quantification of pulmonary vascular leak can be determined with the extravascular lung water index (EVLWI) as determined by the PiCCO system. The patient's EVLWI went from 12 mL/kg after intubation (normal range 3–7) to 25 mL/kg within 3 days (days 9–12; figure 1). Vascular leak syndrome can lead to multiorgan failure induced by oedematous tissue damage (ie, renal failure and liver insufficiency).

### Treatments

#### Use of FX06

Because the patient's pulmonary vascular leak syndrome was worsening, the ethics committee of Frankfurt University Hospital approved the use of a fibrin-derived peptide, Bβ<sub>15–42</sub> (FX06; MChE-F4Pharma, Vienna, Austria), which is under clinical development for vascular leak syndrome, in the attempt to prevent further leakage. On day 11, the patient received 400 mg FX06 intravenously (200 mg as a slow bolus injection followed 10 min later by an additional 200 mg bolus injection) as a starting dose, plus 200 mg intravenous bolus every 12 h for three consecutive days. We paused renal replacement therapy for 30 min after each application to avoid premature clearance from the blood.

An emergency kit was dispatched from the storage facility at Bachem (Philadelphia, PA, USA). For future compassionate use, an emergency stock has now been entrusted to the University Hospital Frankfurt for rapid supply within Europe. In the USA, the FX06 is available on short notice from Bachem on a compassionate use basis; all documentations, clinical, and preclinical data are available from the manufacturer by request.

### Intermittent use of favipiravir

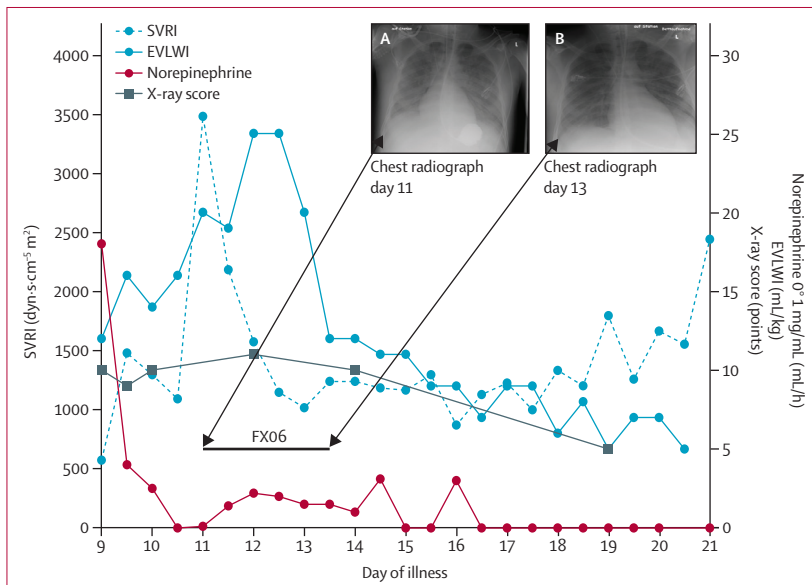
The RNA polymerase inhibitor favipiravir was available for compassionate use. After approval by the ethics committee, we started a treatment attempt, aiming for a dose of 2400 mg twice daily. However, because of the critical gastrointestinal situation and recurrent nausea, the patient was unable to ingest the tablets accordingly and only received 400 mg on day 8 and 1200 mg of favipiravir on day 9 of illness. Because of the development of renal failure and the lack of safety data for patients on renal replacement therapy, we stopped the drug after day 9. No other experimental substances were used.

### Treatment of renal failure

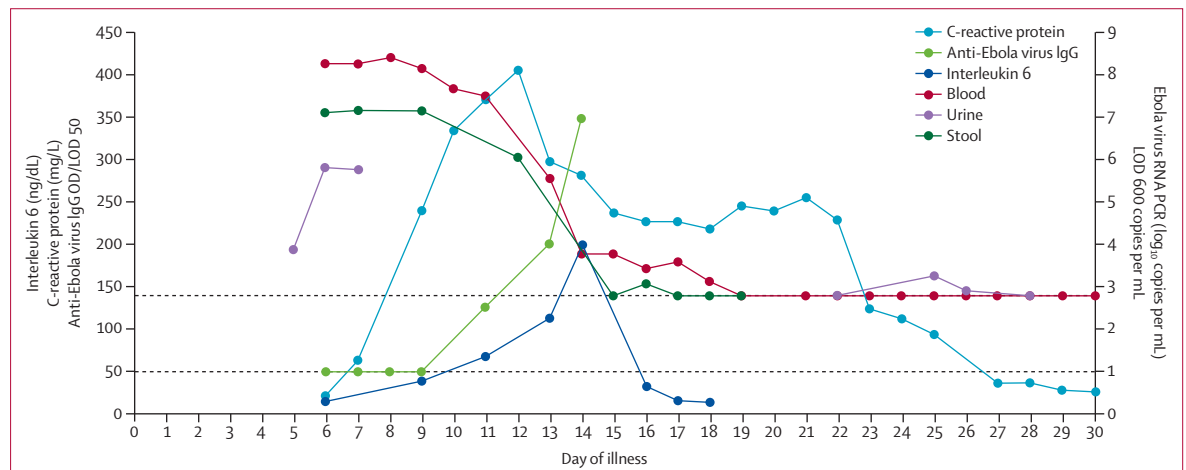
Initially, our patient had oliguric renal failure that could be salvaged with intravenous fluids. The fluid balance on the first day of treatment was positive with 4100 mL. From day 9 onwards, however, the patient became anuric. Ultrasound of the kidneys showed enlarged organs with a hypersonic parenchyma and no hydronephrosis. We initiated a continuous haemodiafiltration (Fresenius CiCa Multifiltrate; Fresenius, Bad Homburg, Germany). The calcium-citrate approach chosen bore less of a risk for haemorrhage. This therapy was given continuously up to day 27. Urine production restarted on day 22. Because phosphate was still elevated, the patient was continued with intermittent haemodialysis every 48 h until day 37.

An important practical aspect of renal replacement therapy was the disposal of liquid waste. Although only one of three waste samples tested positive for Ebola virus RNA (428 copies per mL on day 10; negative on days 18 and 23), the complete liquid waste had to be autoclaved according to local regulations.

On day 13—after the haemodynamic situation had already stabilised—we used a haemofiltration cartridge (Haemopurifier; Aethlon, San Diego, CA, USA) for 6·5 h upstream to the regular system. This cartridge is designed to bind viral glycoproteins by lectin affinity. This one-time use was well tolerated. PCR measurements taken directly before and after the use showed virus loads of  $2\cdot29\times10^5$  copies per mL and  $7\cdot66\times10^4$  copies per mL, respectively. This difference of less than a factor of 3 is within the technical variability range of the RNA PCR assay for Ebola virus and cannot be judged as a notable decrease. Moreover, the use of the filter had no effect on the overall decay kinetics of plasma viraemia in the 4-day period surrounding its application: From day 11 to day 14, viraemia decreased from  $3\cdot20\times10^7$  to  $6\cdot08\times10^3$  RNA copies per mL, and the anti-Ebola-virus IgG titres increased drastically (figure 2).



**Figure 1: Haemodynamics and pharmacological interventions during the clinical course of capillary leak syndrome** Figure shows course of the EVLWI and the SVRI as recorded by PiCCO monitoring system, and norepinephrine treatment and administration of FX06 (from day 11 to day 14, viraemia decreased from  $3\cdot20\times10^7$  to  $6\cdot08\times10^3$  RNA copies per mL, and the anti-Ebola-virus IgG titres increased drastically (figure 2).



**Figure 2: Ebola virus RNA PCR, anti-Ebola-virus IgG, and inflammatory parameters over the course of the illness** Interleukin 6, C-reactive protein, Ebola virus RNA PCR (plasma, stool, and urine), and anti-Ebola-virus IgG titres are shown as a function of the days of disease. The patient was anuric from day 7 to 22, therefore the line for the urine PCR is interrupted. LOD=limit of detection.

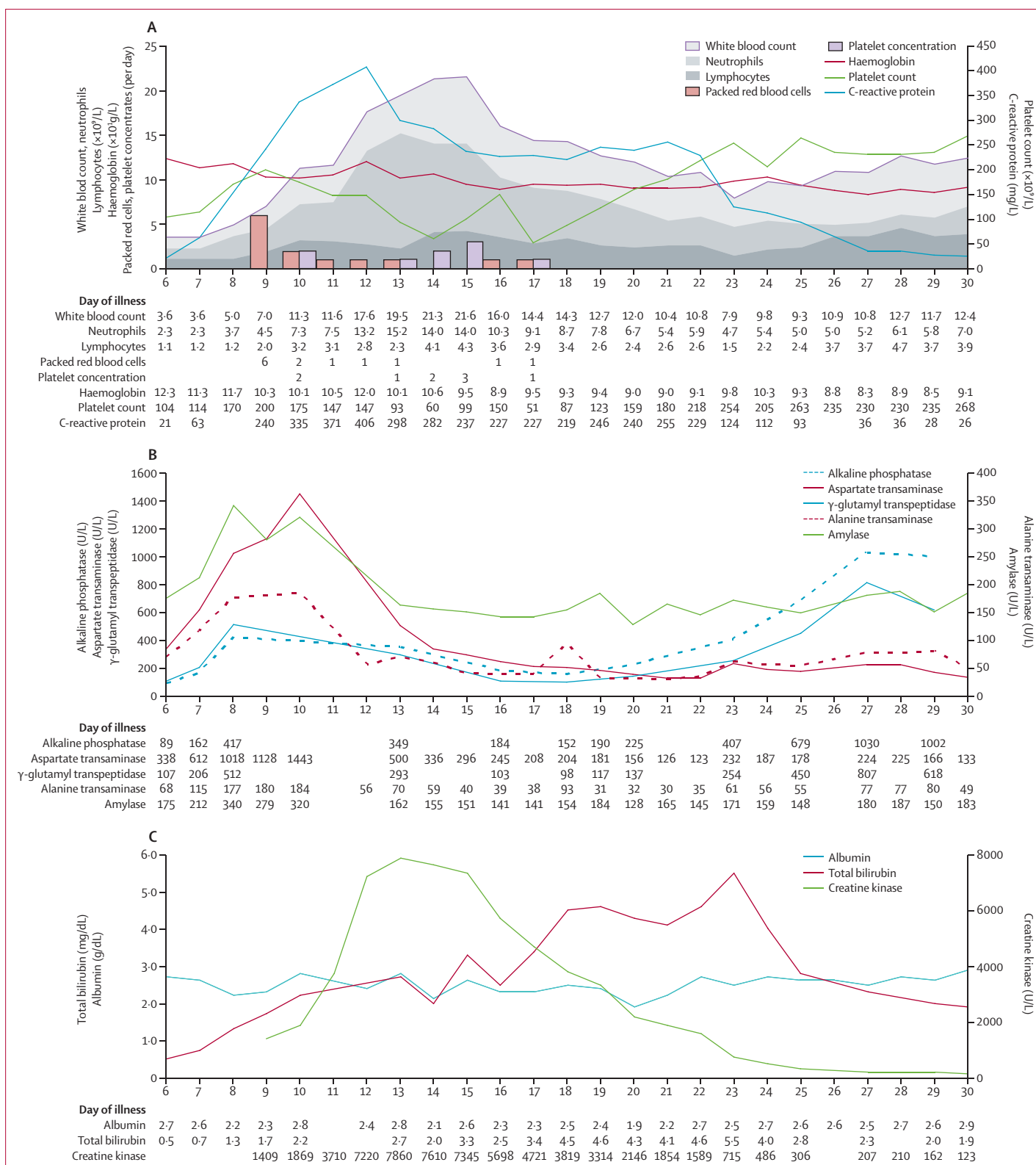


Figure 3: Laboratory parameters shown over the days of illness (days 6–30)

(A) Blood count with platelet concentration and administered red blood cell concentrates. (B) Liver values and serum amylase concentrations. (C) Creatine kinase, albumin, and bilirubin. Numerical values are shown in the tables below the graphs.

### Antimicrobial therapy

Bacterial infection is an important complication in severe Ebola virus disease.<sup>4</sup> Although little information about resistance patterns is available, the use of cephalosporins is high in Sierra Leone,<sup>8</sup> and reports have shown the presence of extended spectrum  $\beta$ -lactamase resistance (Grünwald T, unpublished data).<sup>9</sup> Hence, we started treatment with imipenem-cilastatin on admission. The patient developed a paralytic ileus accompanied by intestinal oedema, and a three-layered gallbladder with pericyclic oedema, all representing sources of bacterial translocation. Because the inflammatory parameters were rising, we switched from imipenem-cilastatin to meropenem and metronidazole (day 9), and later added colistin and anidulafungin (day 10). The patient's clinical condition deteriorated further and inflammatory parameters rose, with C-reactive protein concentrations of 406 mg/L (reference <7), leucocytosis ( $19.5 \times 10^9/L$ , reference 3.8–11.0), and a notable neutrophilia (fraction 0.705) on day 13 (figure 3). At this stage, the viraemia had already declined by three logs (figure 2). Suspecting peritonitis and cholecystitis, we added tigecycline. In the further course, the inflammatory parameters decreased gradually. We gave metronidazole until day 16, tigecycline until day 19, and colistin until day 25, whereas meropenem was given until day 30. Linezolid was added from day 20 to 24 as a substitute for tigecycline to avoid nausea during weaning from mechanical ventilation.

Bacterial cultures could be processed within the isolation area by doctors specialised in infectious diseases and medical microbiology laboratory staff. Repetitive blood and urine cultures and cultures from sputum and pleural effusions did not show growth of relevant pathogens. There was only one coagulase-negative staphylococcus in one of two blood culture bottles from day 11. Anidulafungin-resistant *Candida parapsilosis* was repeatedly detected in pharyngeal swabs. Hence, we used fluconazole as a substitute for anidulafungin on day 20 for another 4 days. Interestingly, despite the severe abdominal disease, we did not detect Gram-negative septicaemia, although a systemic inflammatory response syndrome was apparent.

### Further course of the disease

Figure 1 shows the development of vascular leak syndrome through EVLWI, systemic vascular resistance index, radiograph score, and dosing of norepinephrine. The development of EVLWI peaked at days 11 and 12 with an index value of 25 mL/kg. We gave FX06 from day 11 to 13, and noted improvement of the EVLWI from day 13 onwards. Comparison of the chest radiographs from day 11 and 13 (figure 1) showed improvement of oedema and effusions. The patient needed fairly high doses of norepinephrine immediately after intubation (1.8 mg/h), but subsequently the required doses were low with a maximum of 0.3 mg/h. No vasopressors were needed from day 16 onwards. The patient improved continuously and extubation was possible on day 22.

The observed clinical improvement from day 13 onwards coincided with a decrease of the Ebola virus plasma load and an increase in the titre of anti-Ebola-virus IgG (figure 2). Plasma viraemia fell continuously after day 8 and became undetectable on day 19. Almost simultaneously, the viral RNA in stool samples became undetectable (figure 2). Interestingly, although concentrations of Ebola virus RNA in urine had dropped below the limit of detection on day 24, a PCR signal corresponding to  $1.91 \times 10^3$  RNA copies per mL was noted on day 25. This fluctuation between low and undetectable levels in the urinary tract might underlie the reported viral persistence in seminal fluid.<sup>10</sup>

The course of the laboratory parameters is shown in figure 3. The inflammatory parameters decreased after day 12 for C-reactive protein and day 14 for interleukin 6. Despite an initial leucopenia, both white blood cell count and neutrophil count rose until day 15 and 13, respectively, and subsequently normalised. The platelet count was decreased from day 9 onwards and the patient needed 9 units of platelet concentrates until day 17. We noted no signs of disseminated bleeding, and only the insertion site of the central venous catheter introduced on day 6 showed lengthy bleeding; repeated haemocult tests were negative. The patient received 13 units of red blood cell concentrates until day 17 in response to decreasing haemoglobin concentrations (figure 3). Markers of hepatocyte integrity, including aspartate transaminase and alanine transaminase, were initially elevated and improved after day 10. Of note, direct bilirubinaemia developed later, with a peak at day 23. Albumin concentrations were decreased to levels as low as 19 g/L (reference range 35–52 [1.9 mg/dL, reference range 3.5–5.2 g/dL]), although the patient received albumin substitution until day 20, after which he improved. After the fall in Ebola virus plasma load, the patient improved gradually in all aspects.

### Discussion

This case report shows the feasibility of providing successful intensive care treatment to a patient with Ebola virus disease under biosafety level 4 isolation conditions. Despite the development of vascular leak syndrome and a consecutive multiorgan failure, we managed to support the patient until the development of a potent, adaptive immune response could effectively control the infection. The ensuing respiratory failure was demonstrated by clinical parameters, blood gas analysis, and chest radiograph and by invasive haemodynamic monitoring including EVLWI. Of note, in hyperdynamic systemic inflammatory response syndrome conditions, transpulmonary thermodilution parameters (eg, the global end-diastolic volume index) might not be sufficiently reliable.<sup>11</sup>

Vascular leakage can lead to multiorgan failure induced by oedematous tissue damage. The question of whether the release of cytokines or interaction of viral proteins

with the endothelium itself causes the leakage in Ebola virus disease is still under debate. Early in infection, the cytokines released from infected macrophages are thought to induce leakage,<sup>12</sup> because in animal models infection of the endothelium is negligible at this timepoint. Later, however, virus can also be detected in endothelia and might then contribute to vascular leak syndrome.<sup>13</sup> The endovascular permeability failure in vascular leak syndrome can lead to the loss of intravascular proteins such as coagulation factors, and cellular deficits such as thrombocytopenia.<sup>14</sup> The shift of intravascular fluids can cause fatal lung oedema and the need to ventilate the patient mechanically, often requiring high inspirational peak and positive end-expiratory pressures. This development prolongs the duration of artificial respiration and can lead to poor outcomes,<sup>15</sup> increasing the risk of life-threatening complications (most notably pulmonary permeability oedema).<sup>16</sup> In settings with little access to radiography or PiCCO measurements, reduced oxygen saturation or difficulties breathing could be the first signs of compromised pulmonary function possibly due to vascular leak syndrome in the lung, particularly when the mucous membranes are dry.

FX06, a peptidic compound under clinical development for vascular leak syndrome, was given (to our knowledge) for the first time to a patient with Ebola virus disease, and this treatment coincided with a substantial improvement of both vascular leak syndrome parameters and respiratory function. The safety and efficacy of FX06 in the treatment of vascular leak syndrome has previously been explored in animal models of lipopolysaccharide-induced and dengue haemorrhagic shock.<sup>17</sup> The substance was well tolerated in a phase 2 clinical trial in patients with ST-elevation myocardial infarction.<sup>18</sup> In our patient, we noted no signs of tolerability problems or compromised safety. The improvement of the vascular leak syndrome, however, also coincided with a decrease in the plasma viral load. Shortly after this case, a patient with severe Ebola virus disease (who had been airlifted to Hospital St Georg in Leipzig, Germany) was treated with FX06 from day 11 until 13 after disease onset. After day 10, this patient had diffuse haemorrhage. No compartmentalisation of fluids into lungs, pleura, or peritoneum (EVLWI was always <15 mL/kg) was documented. He died on day 13.

On the basis of our experience, we feel that FX06 warrants further evaluation in the treatment of vascular leak syndrome in Ebola virus disease. Up to this point, two dosing regimens for FX06 have been tested: continuous infusion or, alternatively, two bolus injections every 12 h in patients with kidney failure. FX06 bulk material can presently be supplied by the manufacturer, which would then have to be prepared by a pharmacy on site. Stability data are available for 6 months' storage at a temperature of 25°C.

The cause of the renal failure in our patient was not fully elucidated because of the limitations in available

diagnostics. Initially, substantial erythrocyturia and proteinuria were detectable, which can be indicative of nephritis. Glomerular and tubular necrosis in addition to interstitial lymphocytosis have been documented post mortem in kidney tissues of patients who died of Ebola virus disease.<sup>19</sup> On admission, our patient was severely volume depleted, which probably contributed to his kidney failure.

Severe abdominal symptoms are one of the most frequent manifestations of Ebola virus disease in the current epidemic.<sup>2,4,8</sup> Similarly, gastrointestinal failure with haemorrhage, nausea, and anorexia has been reported in patients with vascular leak syndrome.<sup>20</sup> Initially, our patient showed features of paralytic ileus, pan-enteritis, cholecystitis, peritonitis, and elevated pancreatic enzymes. The pathogenesis of these could in principle be related directly to Ebola virus infection, the vascular leak syndrome-induced oedema of the intestinal wall, or secondary bacterial peritonitis. Under a regimen of broad-spectrum antibiotic therapy, no major bacterial complications occurred. Whether the cause of these gastrointestinal symptoms was mainly viral or bacterial thus remains unclear.

This report emphasises the complexity and specific challenges of intensive care treatment of patients with Ebola virus disease (comparison of reported cases shown in appendix). We suggest FX06 as a potentially valuable therapeutic candidate for vascular leak syndrome in Ebola virus disease. In view of the urgency for action in light of the current epidemic, where validated therapies are desperately needed, the efficacy of FX06 should soon be assessed in clinical trials or at least by standardised collection of data from patients with Ebola virus disease who received it in a compassionate use setting.

#### Contributors

TW, OTK, KZ, and TV did the literature research, TW, KZ, and H-RB designed the study, TW, KZ, TB, SB, VAJK, and GK analysed the data. TW, OTK, KZ, H-RB, TB, VAJK, TG, CS, and SB interpreted the data. TW, KZ, and SB wrote the report. OTK edited the report. TW, KZ, CS, GK, PdL, TG, and H-RB were involved in care of the patient.

#### Declaration of interests

We declare no competing interests.

#### Acknowledgments

We thank our patient for informed consent and the many nurses, doctors, and technical and supporting staff, without whose assistance the outcome in this severe case would likely have been fatal. We wish to thank the patient and his family for the consent to publish this case. We thank Markus Eickmann, and all the staff of the BSL 4 laboratory of the University of Marburg virological analysis and catalytic discussions: Anne Kelterbaum (née Brüggemann), Gordian Schudt, Alexandra Kupke, Nadine Biedenkopf, Svenja Wolf, Verena Krähling, Hosam Shams-Eldin, Jörg Schmidt, Erik Dietzel, Olga Dolnik. We also thank the following physicians, namely Gundolf Schüttfort, Johanna Kessel, Bertram Scheller, Mathis Wahrmann, Katrin Heim, Jan-Peter Linke, Til Kiderlen (all University Hospital Frankfurt), Florian Steiner, Bettina Temmesfeld, (both Charité Berlin, Germany), Matthias Breuer (University Hospital Düsseldorf, Germany), Uwe Ziegler and August Stich (Mission Hospital Würzburg, Germany), Michael Seilmaier (Hospital München-Schwabing, Germany), and Claudia Frey (German Army Hospital, Hamburg, Germany) for physicians service.

See Online for appendix

**Role of the funding source**

This study was funded by the University Hospital of Frankfurt, Germany, without external or extramural grants. The study staff provided input into design, conduct, and manuscript development. The pharmaceutical biotech companies MChE-F4Pharma (Vienna, Austria) and Toyama (Tokyo, Japan) provided investigational medications (FX06 and favipiravir, respectively) and Aethlon (San Diego, CA, USA) provided the investigational haemofiltration filter Hemopurifier. None of these companies had input into patient treatment or review of the Article. All authors had full access to the data and vouch for their integrity and accuracy. The authors were solely responsible for final review and approval of the report. The corresponding author had final responsibility for the decision to submit for publication.

**References**

- 1 WHO. Ebola response roadmap situation report. Geneva: World Health Organization, 2014. [http://apps.who.int/iris/bitstream/10665/137510/1/roadmapsitrepre\\_5Nov14\\_eng.pdf?ua=1](http://apps.who.int/iris/bitstream/10665/137510/1/roadmapsitrepre_5Nov14_eng.pdf?ua=1) (accessed Nov 6, 2014).
- 2 Marshall GL, Mehta AK, Varkey JB, et al. Clinical care of two patients with Ebola virus disease in the United States. *N Engl J Med* 2014; published online Nov 12. DOI:10.1056/NEJMoa1409838.
- 3 Parra MJ, Salmeron OJ, Velasco M. The first case of Ebola virus disease acquired outside Africa. *N Engl J Med* 2014; published online Nov 19. DOI:10.1056/NEJMc1412662.
- 4 Kreuels B, Wichmann D, Emmerich P, et al. A case of severe Ebola virus infection complicated by Gram-negative septicemia. *N Engl J Med* 2014; published online Oct 22. DOI:10.1056/NEJMoa1411677.
- 5 Gehring G, Rohrmann K, Atecnhong K, et al. The clinically approved drugs amiodarone, dronedarone and verapamil inhibit filovirus cell entry. *J Antimicrob Chemother* 2014; **69**: 2123–31.
- 6 Murray JF, Matthay MA, Luce J, et al. An expanded definition of the adult respiratory distress syndrome. *Am Rev Respir Dis* 1988; **138**: 720–23.
- 7 Ware LB, Neyrinck A, O Neal HR, et al. California transplant donor network. *Clin Transplant* 2012; **26**: 665–71.
- 8 Schieffelin J, Shaffer JG, Goba A, et al. Clinical illness and outcomes in patients with Ebola in Sierra Leone. *N Engl J Med*, 2014; published online Oct 29. DOI:10.1056/NEJMoa1411680.
- 9 Manenzhe RI, Zar HJ, Nicoll MP, Kaba M. The spread of carbapenemase-producing bacteria in Africa: a systematic review. *J Antimicrob Chemother* 2014; published online Sept 26. DOI:10.1093/jac/dku356.
- 10 Rowe AK, Bertolli J, Khan AS, et al. Clinical, virologic, and immunologic follow-up of convalescent Ebola hemorrhagic fever patients and their household contacts, Kikwit, Democratic Republic of the Congo. Commission de Lutte contre les Epidémies à Kikwit. *J Infect Dis*; 1999; **179** (suppl 1): S28–35.
- 11 Endo T, Kushimoto S, Yamanouchi S, et al. Limitations of global end-diastolic volume index as a parameter of cardiac preload in the early phase of severe sepsis: a subgroup analysis of a multicenter, prospective observational study. *J Intensive Care* 2013; **1**: 11.
- 12 Feldmann H, Geisbert TW. Ebola hemorrhagic fever. *Lancet* 2011; **377**: 849–62.
- 13 Srikiatkachorn A, Kelley JF. Endothelial cells in dengue hemorrhagic fever. *Antiviral Res* 2014; **109**: 160–70.
- 14 Baluna R, Vitetta ES. Vascular leak syndrome: a side effect of immunotherapy. *Immunopharmacology* 1997; **3**: 117–32.
- 15 Hamada Y, Kawachi K, Tsunooka N, Nakamura Y, Takano S, Imagawa H. Capillary leakage in cardiac surgery with cardiopulmonary bypass. *Asian Cardiovasc Thorac Ann* 2004; **12**: 193–97.
- 16 Czikora I, Sridhar S, Gorshkov B, et al. Protective effect of growth hormone-releasing hormone agonist in bacterial toxin-induced pulmonary barrier dysfunction. *Front Physiol* 2014; **5**: 259.
- 17 Groeger M, Pasteiner W, Ignatyev G, et al. Peptide B $\beta_{35-42}$  preserves endothelial barrier function in shock. *PLoS One* 2009; **4**: e5391.
- 18 Atar D, Petzelbauer P, Schwitter J, et al. Effect of intravenous FX06 as an adjunct to primary percutaneous coronary intervention for acute ST-segment elevation myocardial infarction: results of the F.I.R.E. (Efficacy of FX06 in the Prevention of Myocardial Reperfusion Injury) trial. *J Am Coll Cardiol* 2009; **53**: 720–29.
- 19 Martines RB, Ng DL, Greer PW, et al. Tissue and cellular tropism, pathology and pathogenesis of Ebola and Marburg Viruses. *J Pathol* 2014; published online Oct 9. DOI:10.1002/path.4456
- 20 Amlot PL, Stone MJ, Cunningham D, et al. A phase I study of an anti-CD22-deglycosylated ricin A chain immunotoxin in the treatment of B-cell lymphomas resistant to conventional therapy. *Blood* 1993; **82**: 2624–33.